

SHORT COMMUNICATION

A Potential Method for Safe Recovery from Recognized Inadvertent Esophageal Intubation

Brian Milne and Jessica E. Burjorjee*

Department of Anesthesiology & Perioperative Medicine, Queen's University and Kingston General Hospital, Kingston, Canada

Abstract: How to proceed following inadvertent esophageal intubation and what to do with the misplaced endotracheal tube is controversial and not specifically addressed in the difficult airway algorithm from the American Society of Anesthesiologists.

Here we describe a simple and effective strategy to manually ventilate the patient with an air cushioned face mask while leaving the endotracheal tube in the esophagus to provide a conduit for stomach content suction until definitive endotracheal intubation. We describe clinical circumstances in which we used this method successfully.

Whether to leave the endotracheal tube in the esophagus or what to do with it should be specifically addressed in difficult airway algorithms.

Keywords: American Society of Anesthesiologist's (ASA) Difficult Airway Algorithm, Esophageal intubation, Difficult airway, Intubation method, Patient safety.

1. INTRODUCTION

How to proceed following inadvertent esophageal intubation and what to do with the misplaced endotracheal tube is controversial and not specifically addressed in the difficult airway algorithm from the American Society of Anesthesiologists [1, 2]. Following recognition of an esophageal intubation, it is often routine and instinctive practice to remove the endotracheal tube prior to manual bag-mask ventilation or before proceeding with securing the airway. During this time however, the patient is at risk for aspiration as well as hypoxemia. In a review of morbidity associated with accidental esophageal intubation, Mort reports rates of regurgitation (24.7%), aspiration (12.8%) severe hypoxemia (25%) [3]. Other injuries such as esophageal tear, gastric rupture, or entry of a foreign body are more unusual complications after a difficult tracheal intubation and inadvertent esophageal intubation, but may occur even when recognized immediately [4-6].

Subsequent definitive airway management may also be difficult and prolonged delay may lead to hypoxia, arrhythmias and cardiac arrest. A simple and effective strategy was developed to manually ventilate the patient with an air cushioned face mask while leaving the endotracheal tube in the

esophagus to provide a conduit for stomach content suction prior to definitive endotracheal intubation. The esophageal endotracheal tube was subsequently removed and replaced by a standard nasogastric tube. Here we briefly describe our method for safe recovery from inadvertent esophageal intubation and describe clinical circumstances in which it has been used successfully.

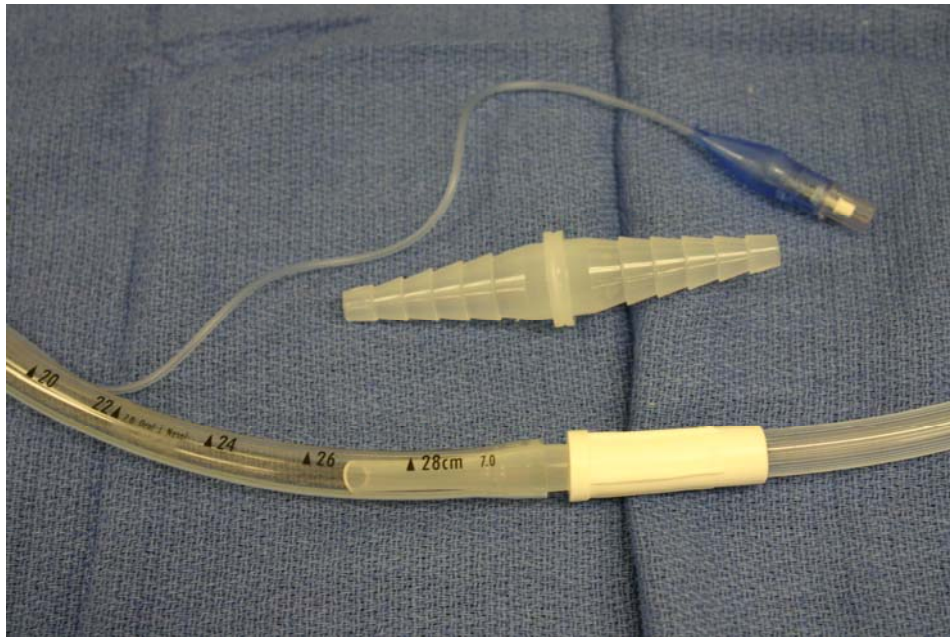
2. REPORT

Institutional Ethics Board approval was obtained to describe the following cases in which our method for recovery from inadvertent esophageal intubation was used.

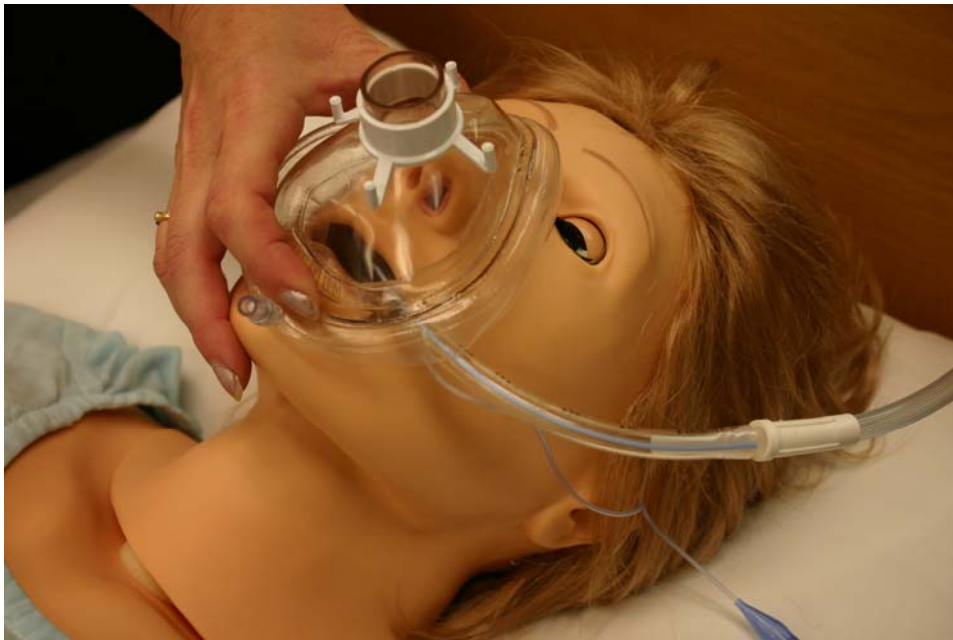2.1. Method Description

Following recognition of inadvertent esophageal intubation, the standard 15 mm endotracheal tube connector is replaced with, either a standard nasogastric tube double-tapered connector or a Medi-Vac® 5 in 1 straight polypropylene tubing connector and this is hooked up to suction tubing (Fig. 1) to evacuate stomach contents. Next a transparent air cushioned facemask (Westmed®) is applied while bending the endotracheal tube down the left side of the face and manual bag-mask ventilation started (Fig. 2). After adequate oxygenation, the airway can be secured with other options with minimal aspiration risk. The method described here makes it easy to maintain an adequate seal and provide patient ventilation with the facemask, while allowing for continuous suction of stomach contents. Following success-

*Address correspondence to this author at the Department of Anesthesiology and Perioperative Medicine, Queen's University, Victory 2, Kingston General Hospital, 76 Stuart Street, Kingston, Ontario, K7L 2V7 Canada; Tel: (613) 548-7827; Fax: (613) 548-1375; E-mail: burjorjj@kgh.kari.net



Figs. (1). Following inadvertent esophageal intubation, the endotracheal tube connector is replaced with the standard nasogastric tube double tapered connector or a Medi-Vac® 5 in 1 straight polypropylene tubing connector (Fig. 1) and this is hooked up to standard suction tubing to evacuate stomach contents.



Figs. (2). A transparent air-cushioned face mask (Westmed®) is applied while bending the endotracheal tube down the left side of the face and manual oxygen-bag-mask ventilation started (Fig. 2).

ful endotracheal intubation, the esophageal tube is removed and replaced with a nasogastric tube.

2.2. Case Descriptions

We have used this technique successfully in morbidly obese patients with full stomachs and in a difficult airway case involving a cervical spinal fracture and bowel obstruction. These patients were all at high risk of aspiration. Esophageal intubation was immediately recognized by standard methods including absence of end tidal carbon dioxide on

capnography and the method described above was utilized. Successful suctioning of stomach contents *via* the esophageal endotracheal tube avoided any potential pulmonary aspiration. In the latter case, ventilation was easily managed avoiding hypoxemia and the airway secured with the aid of a GlideScope®. Performance of blind nasal intubation following inadvertent esophageal intubation was also facilitated by using this technique since the presence of the esophageal endotracheal tube provided anterior direction to the nasal tube.

3. DISCUSSION

Many articles discuss methods of recognizing inadvertent esophageal intubation but offer little guidance on how to proceed when it occurs. Although simple, the method described here would allow effective ventilation in many patients while still providing a conduit for the suction of gastric contents. It may be a useful and inexpensive bridging technique in difficult airway management and may help to avoid aspiration and hypoxemia. The option to perform a blind nasal intubation is also made more feasible since intubation of the trachea is easier with esophageal occlusion as it provides anterior direction to the endotracheal tube. Whether to leave the endotracheal tube in the esophagus or remove it should be specifically addressed in difficult airway management algorithms.

CONFLICT OF INTEREST

The authors have no commercial association or any other interests that may pose a conflict of interest.

ACKNOWLEDGEMENTS

The authors would like to thank Rachel Phelan for assistance with the preparation of this manuscript. This work was presented as a poster at the 2012 Annual meeting of the Canadian Anesthesiologists' Society, Quebec City, Canada.

REFERENCES

- [1] American Society of Anesthesiologists. Practice guidelines for management of the difficult airway: an updated report by the American Society of Anesthesiologists Task Force on Management of the Difficult Airway. *Anesthesiology* 2003; 98: 1269-77.
- [2] Henderson JJ, Popat MT, Latta IP, Pearce AC. Difficult Airway Society guidelines for management of the unanticipated difficult intubation. *Anaesthesia* 2004; 59: 675-94.
- [3] Mort TC. Esophageal intubation with indirect clinical tests during emergency tracheal intubation: a report on patient morbidity. *J Clin Anesth* 2005; 17: 255-62.
- [4] Hilmi IA, Sullivan E, Quinlan J, Shekar, S. Esophageal Tear: An unusual complication after difficult endotracheal intubation. *Anesth Analg* 2003; 97: 911-14.
- [5] Schwadron E, Moses Y, Weissberg D. Gastric rupture complicating inadvertent intubation of the esophagus. *Can J Surg* 1996; 39: 487-9.
- [6] Gronczewski CA. The lost endotracheal tube: an unreported complication of prehospital intubation. *Pediat Emerg Care* 2005; 21: 318-21.

Received: April 28, 2013

Revised: May 15, 2013

Accepted: May 16, 2013

© Milne and Burjorjee; Licensee *Bentham Open*.

This is an open access article licensed under the terms of the Creative Commons Attribution Non-Commercial License (<http://creativecommons.org/licenses/by-nc/3.0/>) which permits unrestricted, non-commercial use, distribution and reproduction in any medium, provided the work is properly cited.