



# The Open Anesthesia Journal

Content list available at: <https://openanesthesiajournal.com>



## REVIEW ARTICLE

### Acoustical Respiratory Monitoring: Historical and Modern Aspects

D. John Doyle\*

Department of General Anesthesiology, Cleveland Clinic, Abu Dhabi, UAE

**Abstract:** This brief review introduces the reader to some of the various historical and modern methods that are available for the bio-acoustical assessment of patient breathing, with other bio-acoustical processes discussed peripherally. Some simple methods of respiratory assessment of historical interest are first discussed, along with more modern methods of patient acoustical monitoring based on advanced analytic methods.

**Keywords:** Bio-acoustics, Breath sounds, Masimo Acoustic RR, Phonocardiogram, Stridor, Wheezes.

#### Article History

Received: February 21, 2019

Revised: May 17, 2019

Accepted: June 6, 2019

## 1. INTRODUCTION

The need for simple yet reliable means of respiratory monitoring has existed since the earliest of times. In antiquity (and even today), respiratory monitoring is relied on careful observation of breathing patterns, focusing especially on rate and rhythm as well as contributions from the diaphragm, thorax (intercostal muscles), and accessory muscles<sup>i</sup>. The origins of cardiorespiratory patient assessment *via* acoustical technology begins with the invention of the stethoscope<sup>ii</sup> by the French physician Rene Theophile Hyacinthe Laënnec (1781-1826) [1]. In his time, auscultation was carried out rather crudely with the physician placing his ear directly on the patient's chest (Fig. 1). Laënnec, said to be seeking some modesty for a buxom young female patient he was about to examine, instead used a roll made from sheets of paper and placed between his ear and the woman's chest. This turned out to be a surprisingly effective acoustic interface, and the improvisation soon led to a more formal design based on wood and brass (Fig. 2). Decades later, the traditional binaural stethoscope was developed, followed by a series of technical improvements such as the 1925 radio broadcasting of heart sounds<sup>iii</sup> or teaching models designed to allow multiple clinicians to listen simultaneously (Fig. 3). Sophisticated electronic systems now exist that offer advanced features such as color spectrographic phonocardiogram analysis [2] or digital subtraction phonocardiography [3] (Figs. 4 and 5).

One adjunct to respiratory monitoring that was popular in the past decades but is rarely used today is to tape a wisp of cotton wool to the upper lip so that it is positioned under one of the nostrils, and watch it move with each breath (Fig. 6). In the

operating room in decades past, before advanced monitors became available, continuous respiratory monitoring was also achieved using an innovative arrangement such as that shown in (Fig. 7).

In contemporary medicine, the need for respiratory monitoring has become especially important with the heavy use of opioids and other respiratory depressants during perioperative care. Despite this clear clinical need, no simple and highly dependable method of continuous respiratory monitoring has come into routine clinical use, although the Masimo system [4 - 6] (Fig. 8) and capnography [7 - 11] come close.

Some methods of respiratory monitoring for unintubated patients are as follows:

- (1) Direct observation of chest and abdominal movements.
- (2) Nasal/oral capnography.
- (3) Nasal/oral thermistor methods (thermistor warms up with expired gases).
- (4) Use of respiratory monitoring belts (chest plus abdominal; several subtypes).
- (5) Extraction of respiratory information from the photoplethysmograph signal.
- (6) Electrical impedance methods (uses a small injected electrical current).
- (7) Acoustic methods (*e.g.*, Masimo system for acoustic respiratory rate monitoring (Fig. 8), color spectro-graphic analysis (Fig. 9).
- (8) Direct observation of chest and abdominal movements.

For intubated patients, respiratory monitoring is somewhat easier, for example using various implementations of airway.

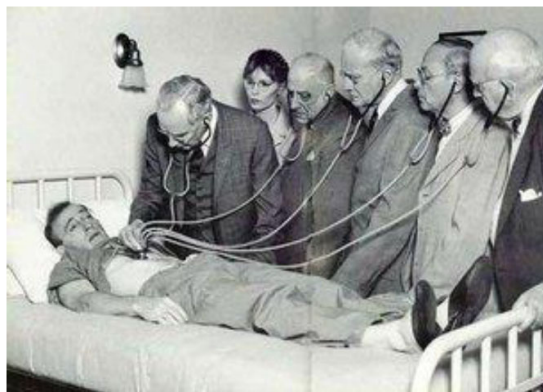\* Address correspondence to this author at Department of General Anesthesiology, Cleveland Clinic, Abu Dhabi, UAE; Tel: +971(0)526997627; E-mail address: [djdoyle@hotmail.com](mailto:djdoyle@hotmail.com)



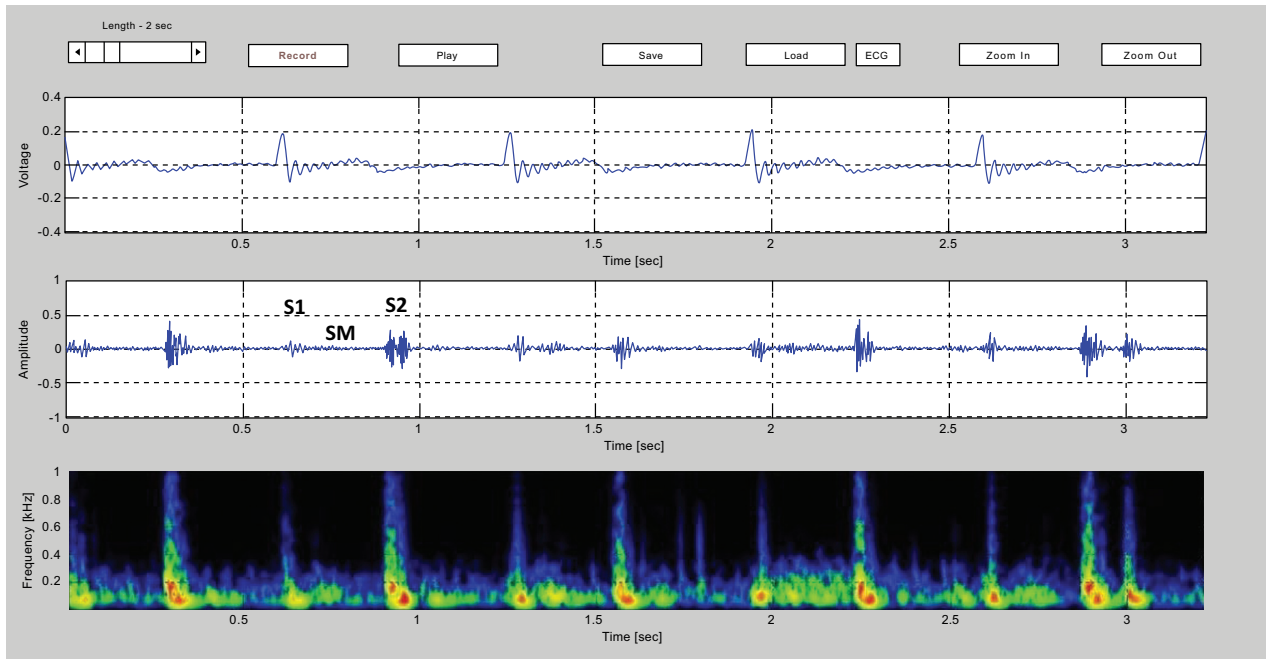
**Fig. (1).** Public domain painting (1889) by Spanish artist Luis Jiménez Aranda (1845-1928) showing a medical professor demonstrating “immediate auscultation” to his students by placing his ear directly on the patient’s back to search for pathological sounds such as those associated with tuberculosis.



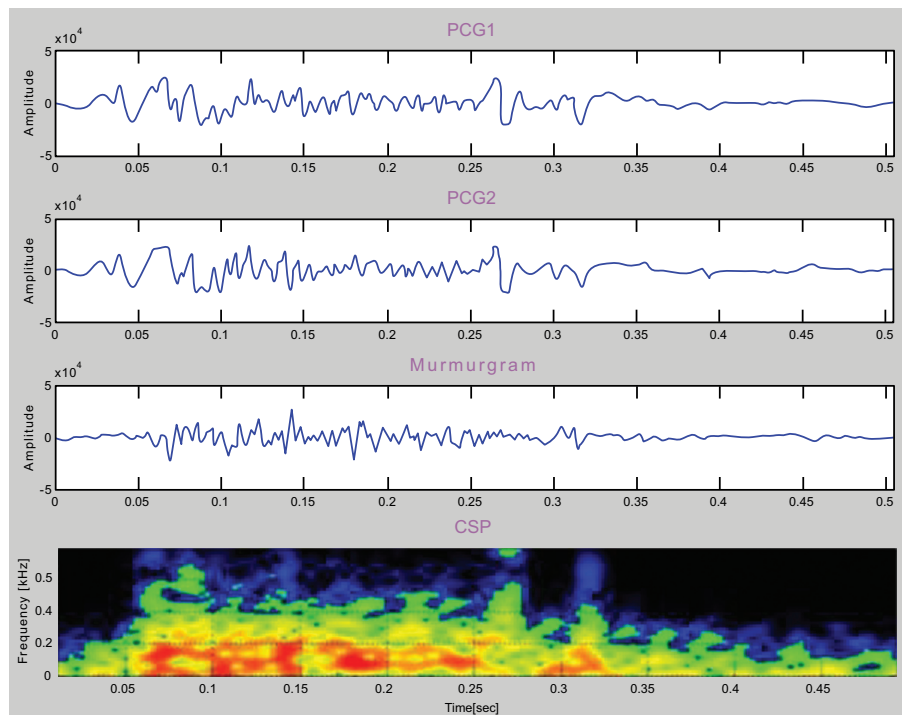
**Fig. (2).** Laennec's original monaural stethoscope. French physician Rene Theophile Laennec (1781-1826) invented the first stethoscope in 1816, which consisted of a simple hollow tube acoustically linking the auscultator’s ear to the patient’s chest. Before this invention, auscultation involved the awkward positioning of the auscultator’s ear directly on the patient’s chest. The more familiar binaural stethoscope, with tubing going to both ears, was not developed until the 1850s. Wikipedia images used under license as follows: **Left:** [https://upload.wikimedia.org/wikipedia/commons/a/a6/Rene-Theophile-Hyacinthe\\_Laennec\\_Drawings\\_stethoscope\\_1819.jpg](https://upload.wikimedia.org/wikipedia/commons/a/a6/Rene-Theophile-Hyacinthe_Laennec_Drawings_stethoscope_1819.jpg) **Right:** Science Museum London / Science and Society Picture Library - Laennec's stethoscope, c 1820. Uploaded by Mrjohncumings, CC BY-SA 2.0, <https://commons.wikimedia.org/w/index.php?curid=28024289>.



**Fig. (3).** One variation of the contemporary binaural stethoscope allows for multiple clinicians to listen simultaneously. Image Credit: <http://www.richardbogle.com/uploads/1/6/7/1/16713358/7979261.jpg>.



**Fig. (4).** Stethoscopes have now evolved into advanced electronic systems that offer features such as color spectrographic analysis. Shown here is the electrocardiogram (top), phonocardiogram (middle) and color spectrogram (bottom) obtained from a healthy six-year-old girl with an innocent systolic murmur. S1=first heart sound; S2=second heart sound; SM=systolic murmur. Image used under a Creative Commons Attribution License 4.0 from Sarbandi RR, Doyle JD, Navidbakhsh M, Hassani K, Torabiyan H. A Color Spectrographic Phonocardiography (CSP) applied to the detection and characterization of heart murmurs: preliminary results. Biomed Eng Online. 2011 May 31;10:42. doi: 10.1186/1475-925X-10-42. PubMed PMID: 21627809; PubMed Central PMCID: PMC3126734.



**Fig. (5).** Digital subtraction phonocardiography offers one the ability to separate the deterministic components of heart sounds (typically S1 and S2) from associated murmurs *via* digital subtraction. In this patient with a systolic murmur from a VSD (Ventricular Septal Defect) two successive heart sound cycles (PCG1 and PCG2) are subtracted to produce a “murmurgram” whose Color Spectrogram (CSP) is presented in the bottom panel. Image used under a Creative Commons Attribution License 4.0 from Akbari MA, Hassani K, Doyle JD, Navidbakhsh M, Sangargir M, Bajelani K, Ahmadi ZS. Digital Subtraction Phonocardiography (DSP) applied to the detection and characterization of heart murmurs. Biomed Eng Online. 2011 Dec 20;10:109. doi:10.1186/1475-925X-10-109. PubMed PMID: 22185298; PubMed Central PMCID:PMC3258229.

pressure measurement, spirometry or pneumotachography to get quantitative data not ordinarily available to unintubated patients.

Of the methods of respiratory monitoring mentioned above, capnography is amongst the most popular method of continuous respiratory monitoring but suffers from a need to continually ensure that the gas sampling system is operating correctly. Extraction of respiratory information from the pulse oximeter photoplethysmograph signal remains a field of active research [12 - 19], but has not yet come into the mainstream. A device known as the ExSpirom 1Xi Monitor Pack (Respiratory Motion Inc., Waltham, MA) operates by detecting electrical impedance changes in the thorax and other structures and seems to be particularly promising, but is neither simple nor inexpensive [20 - 22].

One possible technology for respiratory monitoring that has interested the author for some time is the use of color spectrographic analysis of respiratory sounds. Motivated by the success of color spectrographic techniques in the diagnostic monitoring of rotating machinery [23] and the analysis of bird calls [24], the author set about to build his own system for bio-acoustical research with the goal of developing a research platform for the color spectrographic analysis of respiratory sounds (Fig. 9). The results of these investigations will be reported in future papers.

## 2. DIRECT AND INDIRECT LISTENING TO BREATH SOUNDS

Precordial stethoscope and esophageal stethoscopes are often used to listen to breath sounds as well as heart sounds, although both are used almost exclusively during surgical anesthesia. Precordial stethoscopes typically employ a weighted chest piece or a conventional stethoscope head in contact with the chest, while esophageal stethoscopes are typically soft, thin-walled tubes inserted into the esophagus in the unconscious patient. Esophageal stethoscopes usually feature a distal cuff designed to optimize sound transmission and a male Luer connector for attachment to standard earpieces. Many models support core body temperature measurement as well. Both types of stethoscopes can be very useful in monitoring changes in breath sounds or other bioacoustic phenomena. Examples include the detection of crackles, wheezes and unilateral ventilation resulting from deliberate or inadvertent endobronchial intubation. An excellent detailed review on lung auscultation is available for readers seeking additional information [25].

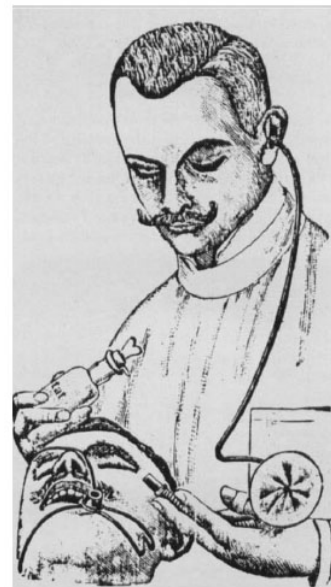<sup>i</sup> For a wonderful video that deals with the various patterns of breathing under ether anesthesia, visit [https://www.youtube.com/watch?v=hVY\\_PTiV90k](https://www.youtube.com/watch?v=hVY_PTiV90k) (The signs and stages of anaesthesia: No. 1 (1944)).

<sup>ii</sup> The word stethoscope is a combination of two Greek words, *stethos* (chest) and *scopos* (examination). But perhaps the word “stethophone” would have been a better choice (see *JAMA*. 1913;61(25):2260. doi:10.1001/jama.1913.04350260058026).

<sup>iii</sup> For a fascinating account of early (1925) work on heart sound transduction, amplification and transmission by radio, visit <https://www.rcplondon.ac.uk/news/certain-thrill-broadcasting-human-heart>



**Fig. (6).** A simple respiratory monitor can be made by taping a piece of cotton wool to the upper lip such that it is placed under one of the nostrils and thus moves with each breath. From the film entitled *Intravenous anaesthesia: No. 6 (1944) Pt. 1 of 2*, available online at <https://www.youtube.com/watch?v=2nz2VnV9Nu0> (Image is taken from time position 10:40).



**Fig. (7).** Illustration of the Kuhn (1844 to 1924) flexometallic endotracheal tube and related airway equipment. This tube was usually placed blindly under anesthesia by inserting one's left hand into the mouth and feeling for the epiglottis and the arytenoid cartilages while the tube was inserted with one's other hand. The correct position of the tube was then established by listening for the correct breath sounds using the attached earpiece. Also shown is the “Trendelenburg Cone” (lower right) used to administer chloroform. (Image credit: *Anaesthesia*, 1985, Volume 40, page 1002).

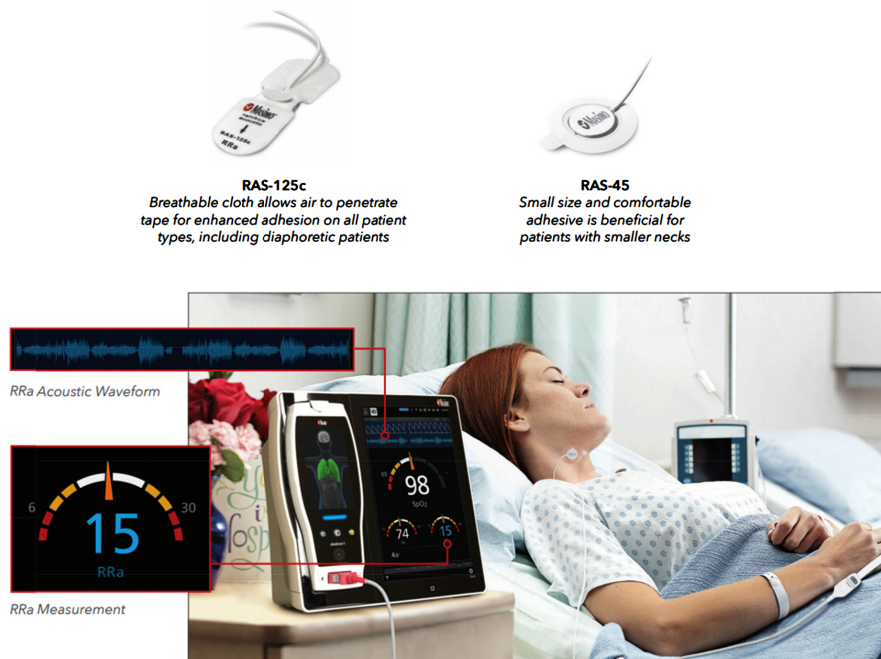One particularly interesting application of esophageal stethoscopes in pediatric surgery is to access whether the characteristic murmur of a patent ductus arteriosus has vanished following surgical ligation [26, 27]. In another study [28] heart sound intensity was seen to decrease with increasing depth of anesthesia and to increase following the administration of ephedrine, a cardiac stimulant.

In addition to directly listening to breath sounds *via* an earpiece, technological innovations have led to developments

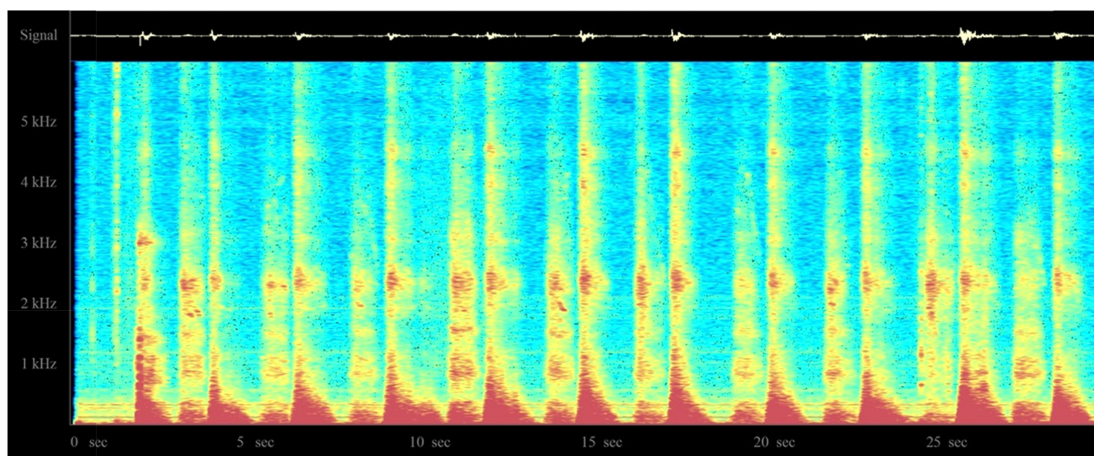
such as the electronic transduction, amplification and transmission of breath sounds as well as in providing methods for advanced computer-based analysis. However, one important aspect central to such undertaking is to evaluate the various stethoscope assemblies to which a microphone is to be attached. I propose to discuss this matter and other technical matters in future papers.

**CONCLUSION**

Although a variety of methods are available for the assessment of patient breathing, bio-acoustical methods of respiratory assessment offer some special advantages that make them attractive to the clinical community.



**Fig. (8).** The Masimo system for acoustic respiratory rate monitoring is a well-established technique for respiratory monitoring. Two forms of available acoustic sensors are available, and both are designed for placement on the neck, near the trachea. The system also includes a pulse oximetry feature, and numerically displays the arterial oxygen saturation, the heart rate and the respiratory rate (known as RRa). Also displayed is the time-domain acoustic waveform, a feature that can be helpful when troubleshooting. While multiple studies have confirmed the value of this method of acoustical respiratory monitoring in a number of settings, the technology as currently available has some important limitations. First, neither the raw nor the processed acoustic signal is available to the clinician to listen to, although the time-domain signal is displayed. The fact that the system does not provide an analog signal output for such purposes also limits the kind of supplementary analysis that might otherwise be performed, such as digitally recording the obtained signals, subjecting the signal to analog or digital filtering, or carrying out real-time color spectrographic analysis of the obtained breath sounds. Also, because of the proprietary nature of the Masimo acoustic monitoring system, little is publicly known about the flat acoustic sensor used. The likelihood, however, is that their sensor is based on piezoelectric film technology, as this technology has proven to be very useful in a variety of clinical applications. Image Credit: [http://www.masimo.com/siteassets/us/documents/pdf/plm-10023b\\_product\\_information\\_rra\\_us.pdf](http://www.masimo.com/siteassets/us/documents/pdf/plm-10023b_product_information_rra_us.pdf)



**Fig. (9).** Sample respiratory sound spectrogram recorded in the authors' laboratory using a miniature electret microphone embedded in an oxygen mask. The range of frequencies displayed in this figure is 0 Hz to 6000 Hz, with the highest frequency signal components at the top, and the lowest at the bottom. Red areas indicate strongest signal levels, blue areas the weakest nonzero levels: BLACK < BLUE < GREEN < YELLOW < RED. Note that both inspiration and expiration are clearly visible. The time-domain signal is displayed at the very top of the image.

**CONSENT FOR PUBLICATION**

Not applicable.

**FUNDING**

None.

**CONFLICT OF INTEREST**

The author declares no conflict of interest, financial or otherwise.

**ACKNOWLEDGEMENTS**

Declared none.

**REFERENCES**

- [1] Lüderitz B. The discovery of the stethoscope by T. R. H. Laënnec (1781-1826). *J Interv Card Electrophysiol* 2009; 26(2): 151-4. [http://dx.doi.org/10.1007/s10840-009-9407-6] [PMID: 19639400]
- [2] Sarbandi RR, Doyle JD, Navidbakhsh M, Hassani K, Torabiyan H. A Color Spectrographic Phonocardiography (CSP) applied to the detection and characterization of heart murmurs: Preliminary results. *Biomed Eng Online* 2011; 10: 42. [http://dx.doi.org/10.1186/1475-925X-10-42] [PMID: 21627809]
- [3] Akbari MA, Hassani K, Doyle JD, *et al.* Digital Subtraction Phonocardiography (DSP) applied to the detection and characterization of heart murmurs. *Biomed Eng Online* 2011; 10: 109. [http://dx.doi.org/10.1186/1475-925X-10-109] [PMID: 22185298]
- [4] Ouchi K, Fujiwara S, Sugiyama K. Acoustic method respiratory rate monitoring is useful in patients under intravenous anesthesia. *J Clin Monit Comput* 2017; 31(1): 59-65. [http://dx.doi.org/10.1007/s10877-015-9822-4] [PMID: 26759335]
- [5] McGrath SP, Pyke J, Taenzer AH. Assessment of continuous acoustic respiratory rate monitoring as an addition to a pulse oximetry-based patient surveillance system. *J Clin Monit Comput* 2017; 31(3): 561-9. [http://dx.doi.org/10.1007/s10877-016-9884-y] [PMID: 27142098]
- [6] Yang S, Menne A, Hu P, *et al.* Acoustic sensor versus electrocardiographically derived respiratory rate in unstable trauma patients. *J Clin Monit Comput* 2017; 31(4): 765-72. [http://dx.doi.org/10.1007/s10877-016-9895-8] [PMID: 27270963]
- [7] Dewdney C, MacDougall M, Blackburn R, Lloyd G, Gray A. Capnography for procedural sedation in the ED: A systematic review. *Emerg Med J* 2017; 34(7): 476-84. [http://dx.doi.org/10.1136/emermed-2015-204944] [PMID: 27565194]
- [8] Conway A, Douglas C, Sutherland J. Capnography monitoring during procedural sedation and analgesia: A systematic review protocol. *Syst Rev* 2015; 4: 92. [http://dx.doi.org/10.1186/s13643-015-0085-4] [PMID: 26170128]
- [9] Nassar BS, Schmidt GA. Capnography during critical illness. *Chest* 2016; 149(2): 576-85. [http://dx.doi.org/10.1378/chest.15-1369] [PMID: 26447854]
- [10] Kodali BS. Capnography outside the operating rooms. *Anesthesiology* 2013; 118(1): 192-201. [http://dx.doi.org/10.1097/ALN.0b013e318278c8b6] [PMID: 23221867]
- [11] Conway A, Douglas C, Sutherland JR. A systematic review of capnography for sedation. *Anaesthesia* 2016; 71(4): 450-4. [http://dx.doi.org/10.1111/anae.13378] [PMID: 26792775]
- [12] Cernat RA, Ciorecan SI, Ungureanu C, Arends J, Strungaru R, Ungureanu GM. Recording system and data fusion algorithm for enhancing the estimation of the respiratory rate from photoplethysmogram. *Conf Proc IEEE Eng Med Biol Soc* 2015; 2015: 5977-80. [http://dx.doi.org/10.1109/EMBC.2015.7319753] [PMID: 26737653]
- [13] Clifton D, Douglas JG, Addison PS, Watson JN. Measurement of respiratory rate from the photoplethysmogram in chest clinic patients. *J Clin Monit Comput* 2007; 21(1): 55-61. [http://dx.doi.org/10.1007/s10877-006-9059-3] [PMID: 17131084]
- [14] Bergese SD, Mestek ML, Kelley SD, *et al.* Multicenter study validating accuracy of a continuous respiratory rate measurement derived from pulse oximetry: A comparison with capnography. *Anesth Analg* 2017; 124(4): 1153-9. [http://dx.doi.org/10.1213/ANE.0000000000001852] [PMID: 28099286]
- [15] Leonard PA, Clifton D, Addison PS, Watson JN, Beattie T. An automated algorithm for determining respiratory rate by photoplethysmogram in children. *Acta Paediatr* 2006; 95(9): 1124-8. [http://dx.doi.org/10.1080/08035250600612280] [PMID: 16938761]
- [16] Addison PS. Respiratory effort from the photoplethysmogram. *Med Eng Phys* 2017; 41: 9-18. [http://dx.doi.org/10.1016/j.medengphy.2016.12.010] [PMID: 28126420]
- [17] Addison PS, Watson JN, Mestek ML, Ochs JP, Uribe AA, Bergese SD. Pulse oximetry-derived respiratory rate in general care floor patients. *J Clin Monit Comput* 2015; 29(1): 113-20. [http://dx.doi.org/10.1007/s10877-014-9575-5] [PMID: 24796734]
- [18] Leonard PA, Douglas JG, Grubb NR, Clifton D, Addison PS, Watson JN. A fully automated algorithm for the determination of respiratory rate from the photoplethysmogram. *J Clin Monit Comput* 2006; 20(1): 33-6. [http://dx.doi.org/10.1007/s10877-005-9007-7] [PMID: 16532280]
- [19] Nakajima K, Tamura T, Miike H. Monitoring of heart and respiratory rates by photoplethysmography using a digital filtering technique. *Med Eng Phys* 1996; 18(5): 365-72. [http://dx.doi.org/10.1016/1350-4533(95)00066-6] [PMID: 8818134]
- [20] Holley K, MacNabb CM, Georgiadis P, Minasyan H, Shukla A, Mathews D. Monitoring minute ventilation versus respiratory rate to measure the adequacy of ventilation in patients undergoing upper endoscopic procedures. *J Clin Monit Comput* 2016; 30(1): 33-9. [http://dx.doi.org/10.1007/s10877-015-9674-y] [PMID: 25735263]
- [21] Voscopoulos CJ, MacNabb CM, Freeman J, Galvagno SM Jr, Ladd D, George E. Continuous noninvasive respiratory volume monitoring for the identification of patients at risk for opioid-induced respiratory depression and obstructive breathing patterns. *J Trauma Acute Care Surg* 2014; 77(3)(Suppl. 2): S208-15. [http://dx.doi.org/10.1097/TA.0000000000000400] [PMID: 25159358]
- [22] Schlesinger JJ. Applications of a noninvasive respiratory volume monitor for critical care medicine. *Respir Care* 2015; 60(5): e97-e100. [http://dx.doi.org/10.4187/respcare.03744] [PMID: 25628450]
- [23] Wang J, Gao RX, Yan R. Multi-scale enveloping order spectrogram for rotating machine health diagnosis. *Mech Syst Signal Process* 2014; 46(1): 28-44. [http://dx.doi.org/10.1016/j.ymssp.2013.06.001]
- [24] Khan AA, Qureshi IZ. Vocalizations of adult male Asian koels (*Eudynamis scolopacea*) in the breeding season. *PLoS One* 2017; 12(10): e0186604. [http://dx.doi.org/10.1371/journal.pone.0186604] [PMID: 29053720]
- [25] Bohadana A, Izbicki G, Kraman SS. Fundamentals of lung auscultation. *N Engl J Med* 2014; 370(8): 744-51. [http://dx.doi.org/10.1056/NEJMr1302901] [PMID: 24552321]
- [26] Nezafati MH, Soltani G, Kahrom M. Esophageal stethoscope: An old tool with a new role, detection of residual flow during video-assisted thoracoscopic patent ductus arteriosus closure. *J Pediatr Surg* 2010; 45(11): 2141-5. [http://dx.doi.org/10.1016/j.jpedsurg.2010.07.017] [PMID: 21034935]
- [27] Kahrom M, Kahrom H. Esophageal stethoscope in thoracoscopic interruption of patent ductus arteriosus. *Asian Cardiovasc Thorac Ann* 2008; 16(4): 288-91. [http://dx.doi.org/10.1177/021849230801600406] [PMID: 18670020]
- [28] Park SH, Shin YD, Bae JH, *et al.* Heart sounds analysis via esophageal stethoscope system in beagles. *J Clin Monit Comput* 2013; 27(5): 535-9. [http://dx.doi.org/10.1007/s10877-013-9459-0] [PMID: 23529343]